



Pet-vision

Ophthalmology Referral Practice

Stephan Termote CertVOphthal MRCVS

27 High Street

Longstanton

Cambridge

CB4 5BP

T: 01954 782 368

F: 01954 782 184

www.pet-vision.co.uk

Summer 06

Newsletter

It is nearly a year since the opening of Pet – vision and I would like to take the opportunity to thank practices and surgeons for sending us cases. Below is a brief overview of some conditions and cases that have been referred within the last 10 months.

Abbreviations used:

KCS: keratoconjunctivitis sicca.

IOP: intraocular pressure

IOL: intraocular lens

PRA: progressive retinal atrophy

Proportional representation of conditions seen:

Eyelid and periocular disease: 7.5 %

Nasolacrimal and lacrimal secretory system abnormalities: 6.7 %

Conjunctival disease: 3.7 %

Third eyelid disease: 4.1 %

Corneal disease: 30.9 %

Scleral disease: 0.5 %

Intraocular disease (lens, uveal tract, vitreous, retina and optic nerve): 36.6 %

Orbital disease: 0.9 %

Glaucoma: 6.4 %

Neuro – ophthalmology: 2.7 %

The classification is based on the dominant part of the eye affected, since one condition can affect several parts of the eye (e.g. KCS) and several abnormalities may be diagnosed during a single examination (e.g. luxated cataract in an eye with chronic uveitis). In fact the figures are not that dissimilar from a similar survey carried out a few years ago (then predominantly mobile clinic). Intraocular disease however features more commonly (mainly due to an increase in cataract cases), whereas surprisingly few cases with conjunctival disease were seen.

Corneal disease was the most common referred condition. About 50 % of this was corneal ulceration, with superficial ulcers (66 %) more common than deep ulceration. Uncomplicated healing was seen in all (canine) **indolent ulcers** managed by lamellar keratectomy and over 90 % of ulcers treated by stromal debridement and grid keratotomy, these procedures of course following thorough epithelial debridement.

Treatment that alters the exposed stroma therefore may be as crucial to rapid healing as the removal of detached epithelium. An interesting observation as well is the variation in vascular response that takes place in corneas with indolent ulcers, with the exceptional case where this response was almost absent even following surgical treatment(s). This contrasts with the more typical vascular response seen (**fig 1**) in cases presenting with advanced and / or debrided indolent ulcers.

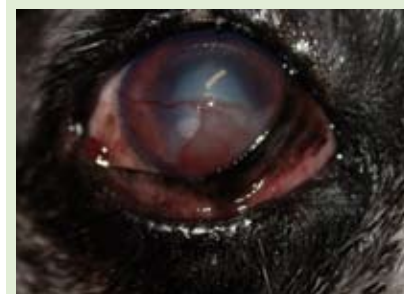

Fig 1. Vascular response more typically seen in advanced and / or debrided indolent ulcers.

Where serum drops were added to the post – operative treatment protocol the observation was that there appears to be significantly faster epithelial re-

surfacing. Serum contains several tear factors (albeit in different concentrations) that are important in maintaining a normal ocular surface (epithelial growth factor, vitamin A, transforming growth factor, fibronectin and other growth factors). Some of these factors have been used individually in the treatment of indolent ulcers. Fibronectin for example has been shown to promote epithelial attachment in both humans and rabbits. A recent study evaluating the efficacy of autologous serum in treatment of epithelial defects in rabbits showed that it induced faster epithelial healing when compared with an artificial tear control group.

(Esquenazi s, He J, Bazan H. Use of autologous serum in corneal epithelial defects post lamellar surgery. British Journal of Ophthalmology 2005; 24(8): 992 – 7).

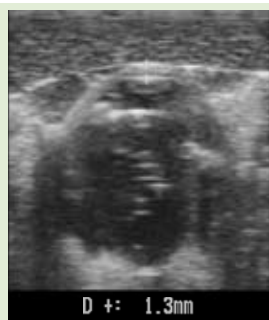

Fig 2. Swelling of the cornea in a Cairn Terrier with endothelial cell dysfunction, demonstrated by ultrasound. The normal (central) corneal thickness in a small dog is approx. 0.6 – 0.7 mm.

Corneal ulceration associated with some degree of **endothelial cell dysfunction** was not uncommon. The extent of corneal oedema seen in these cases is often disproportionate and more severe than would be expected from ulceration, but in large chronic ulcers with intense vascular response this may not be so obvious. Ultrasound examination can demonstrate corneal swelling (**fig 2**) from endothelial dysfunction although

this is not a routine part of the examination protocol in cases with ulceration.

A cluster of cases with **corneal sequestration** was seen and this represented almost 6 % of corneal disease. Feline Herpes virus has long been suspected as a potential cause or factor in the development of corneal sequestration, although there is no evidence of **Herpes** infection in the history or work up in many cases with necrosis. One case (DSH) that underwent an uncomplicated keratectomy for sequestration in the right eye promptly developed acute chemosis in the contralateral eye on leaving the surgery and was diagnosed with an extensive superficial ulcer a few days later. Low levels of Herpes viral DNA were isolated (conjunctival swab), associated with chronic infection or carrier status. This appeared to be the classical case of stress – induced virus recrudescence. Two weeks later there was the beginning of necrosis over the central cornea (area of ulceration). Surgery was carried out on this eye 3 months later after pre – operative treatment with topical interferon.

No complications were seen on this occasion and healing was uneventful.

In cases with suspected **allergic** conjunctival disease, some promising responses were seen following treatment with Opatanol drops (Olopatadine, Alcon), a mast cell stabiliser. Overall there seems to be a steady decline in KCS cases and feline hypertension, which must be due to both earlier detection and improved

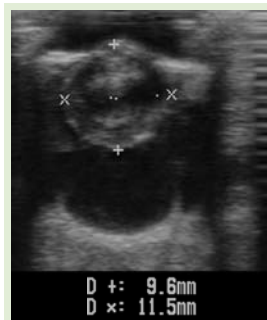

Fig 3. Unusual lens swelling in the right eye of a 7 year old Golden Retriever with bilateral mature cataracts. The axial lens diameter in the left eye was 7.2 mm. The axial diameter of the normal (canine adult) lens varies on average between 6.2 and 7.2 mm.

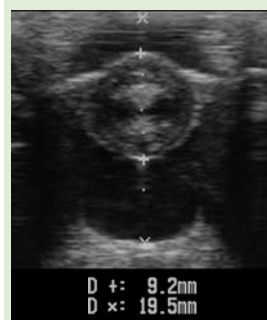

Fig 4. Lens swelling in a diabetic cataract demonstrated by ultrasound. The axial lens diameter here was 9.6 mm.

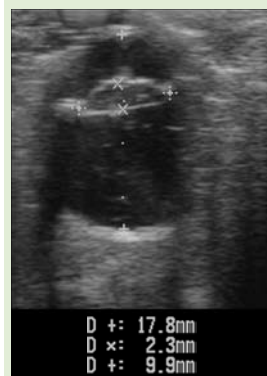

Fig 5. Lens collapse following hypermature cataract in a 3-year-old Cross breed. The lenses in such cases contain predominantly liquefied material together with what remains of the nucleus.

management of these cases. Peripapillary intraretinal haemorrhages may be a subtle sign of hypertension in the dog. My observation (and it is an observation only) is that this type of haemorrhage is more common in the aged Retriever. Some of these patients were subsequently diagnosed with hypertension.

Cataracts were the most common **intraocular** problem. Lens luxation represented 17 % of lens problems. Lens volume changes during cataract progression have been well documented. In maturing and mature cataracts an increase in lens volume is usually not so evident, although we have seen rather unusual swelling in the occasional mature non – diabetic cataract (**fig 3**). In the mature diabetic cataract lens intumescence (swelling) is mainly due to an osmotic process. In some cases swelling can be quite dramatic (**fig 4**). Lens swelling may result in lens rupture and increase in IOP due to compromised aqueous outflow, although this is (at least in my experience) very rare. The increased fluid content in diabetic cataracts does soften up the lens material making phaco – emulsification in most cases a little easier. Hypermature cataracts in contrast often show significantly reduced lens volume, due to liquefaction and loss of lens substance (**fig 5**). This is invariably accompanied

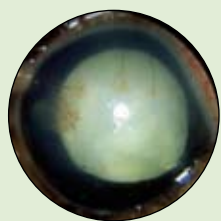


Fig 6. Advanced (hypermaturation) cataract with lens induced uveitis. There is darkening of the iris, beginning of lens liquefaction and keratitis.



Fig 7. End stage cataract resorption in a dog. There is return of the fundus reflex. Such resorption is uncommon and is usually associated with destructive intraocular inflammation. There is posterior synechia formation and lens capsule defect.

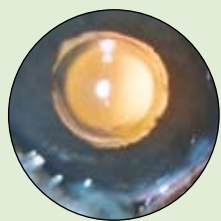


Fig 8. Intraocular lens implant following cataract surgery. The optic of the lens is visible within the (dilated) pupil.

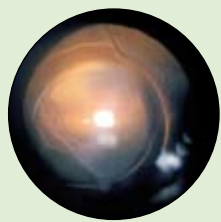


Fig 9. Decentration of an IOL. Note also the opacities representing "folds" or "wrinkles" in the posterior lens capsule. This is a normal postoperative change.

by (lens – induced) uveitis, resulting from sustained leaking of antigenic lens material into the eye (**fig 6**). End – stage cataract resorption (**fig 7**) is uncommon. Although there seems little doubt that visual acuity is better in the majority of dogs which have received an IOL (**fig 8**), those without implants usually benefit from vision more than adequate enough to resume their normal activity. IOL implantation on the other hand is not always free of complications (**fig 9**). The main issue in cataract surgery however, with or without IOL implants, is about the long - term outcome especially in young dogs.

Penetrating ocular injuries (frequently cat claws) damaging the lens (**fig 10**) carry a guarded prognosis, mainly because of phacoclastic uveitis and the complication of resulting cataract or endophthalmitis. The size of the lens capsule defect is thought to be an important factor with regards of predicting the extent of these complications. It is interesting that in some of these cases with substantial defects and severe uveitis at the onset, long – term follow up does not show any evidence of cataract progression or protracted uveitis, unlike in some cases with small defects. Lens capsule tears or defects may be located in the periphery of the lens and easily missed. Following a suspected

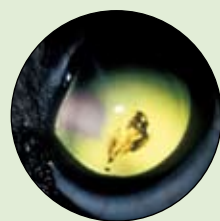

Fig 10. Pigment deposit over the lens capsule months after a penetrating (cat claw) injury in a Yorkshire Terrier. Focal cataract is not evident from this picture.

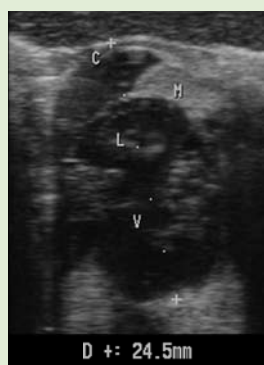

Fig 11. Well defined hyperechoic mass representing an irido – ciliary tumour in a 12 y old Labrador. There is anterior extension of the mass (M = mass, C = cornea, L = lens, V = vitreous).

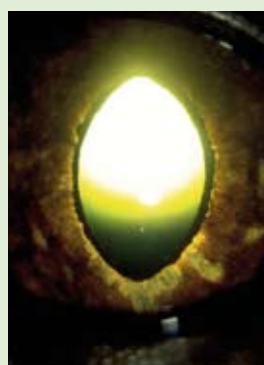


Fig 12. Extensive diffuse increase in iris pigmentation in a DSH. Should this eye be enucleated?

penetrating injury therefore the pupil should be dilated to allow a thorough inspection of the lens.

Uveitis was the more common ocular presentation in the few cases with lymphoma. In one confirmed lymphoma case there was keratitis with dramatic vascular infiltration possibly related to direct tumour invasion, without any (clinical) evidence of intraocular inflammation.

Irido – ciliary adenoma was diagnosed in a Labrador with unilateral (left eye) glaucoma. A mass was identified on ultrasonography (**fig 11**). This tumour is relatively uncommon but still the second most common primary intraocular tumour in the dog. Glaucoma in these cases results from obstruction of the iridocorneal angle through pre – iridal fibrovascular membrane, synechia formation, inflammation and direct tumour extension.

The question as what action to take in **feline** cases with suspect or progressive **iris** pigmentation is always difficult (**fig 12**). When advising enucleation in such cases it is always on the basis of pigment increase together with other criteria such as iris thickening, inflammation or evidence of pupil distortion, pigment dispersion

and findings from tonometry or gonioscopy. Consequently it seems wise to consider diffuse pigmentation in cases with glaucoma and all the above signs not just as benign process, and in these cases the decision to

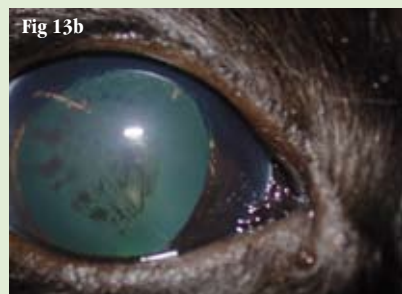

Fig 13.a+b Blind glaucomatous right eye and suspected iris melanoma in a 14 year old DSH. Diffuse increase in iris pigmentation and pigment deposition on the lens.

remove the eye is rather straightforward. There is still the issue of metastasis however, and a true metastatic rate of feline iris melanoma is not known. It is interesting therefore to see cases such as the 14-year-old DSH presented on (**fig 13a&13b**). This patient was diagnosed with glaucoma and had a history of progressive iris pigmentation reportedly from the age of 4.

Histology was mostly consistent with **epithelial inclusion cyst**, a rare condition in the dog. The content of the lesion was identified as nucleated and anucleated squamous epithelial cells. No neutrophils or micro-organisms were seen making corneal abscess less likely. Cyst formation may have been due to down-growth of epithelial cells along the suture wound. Epithelial cells may get trapped or incarcerated in the stroma, resulting in cystic changes and accumulation of desquamated cells. Previous reports of such cysts have also suggested a strong link with previous corneal disease (ulceration) or surgery (keratectomy) in the majority but not all of the cases.

This may just support a process of benign melanosis or may just suggest that melanoma does not invariably carry a fatal prognosis. Anyhow, such a case I believe is an exception and the owners under the circumstances elected not to have the eye enucleated.

The majority of **retinal disease** seen was of a degenerative (PRA or PRA - like) nature.

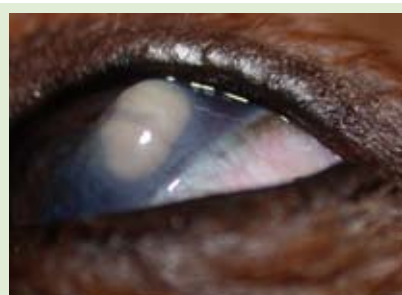

Fig 14. Epithelial inclusion cyst (provisional diagnosis) in a Cavalier King Charles. Cystic yellowish coloured mass within the corneal stroma.

One of our favourite patients, little Pip the Cavalier, has surprised as again with an unusual condition. Pip has over the years had several problems, possibly linked with a peculiar functioning immune system. Now 2

years following corneal surgery for descemetocoele he developed a large yellowish lesion within the corneal stroma, just above the site of previous surgery (**fig 14**).




Fig 15. Doggles !

Finally, an image of Beauty the German Shepherd Dog. Special eye ware to block the effects of UV sun light is available, as we point out to clients of patients with pannus. Few clients rush out to buy these things, but Beauty was the first dog to model them for us (**fig 15**).

I hope this letter has been of interest. Pet – vision is planning an open day towards the end of the summer and we will shortly send you some more information about this. I would like to thank Vet – Index Publications for their much appreciated support and help with the letter. If you would like to refer or discuss a case please do not hesitate to contact us on **01954 782 368**.